NOVARTIS

□□□□□□□□□□□□

□□□□□□□□□□□□

□□□□□□□□□□□□ □□□□□ □□□□□□□□□□ □□ □□

- □□□□
- □□□□
- □□□□□□□□

□□□□□□□□□□□□□□□□□□□□□□□□□□□□□NEDA□no evidence of disease activity□□□□□□□□□□□□□□□4□□□□□□□□□□□NEDA-4□□□□□□□□□**1**□[1-3]□

1. □□□□□
2. □□□□□□□□□
3. MRI□□□□□□□□□□□
4. MS□□□□□□□□□□□□□□□□□□□□

□□□NEDA□□□□□□MS□□□□□□□□□□□□□□□□□□□

Image

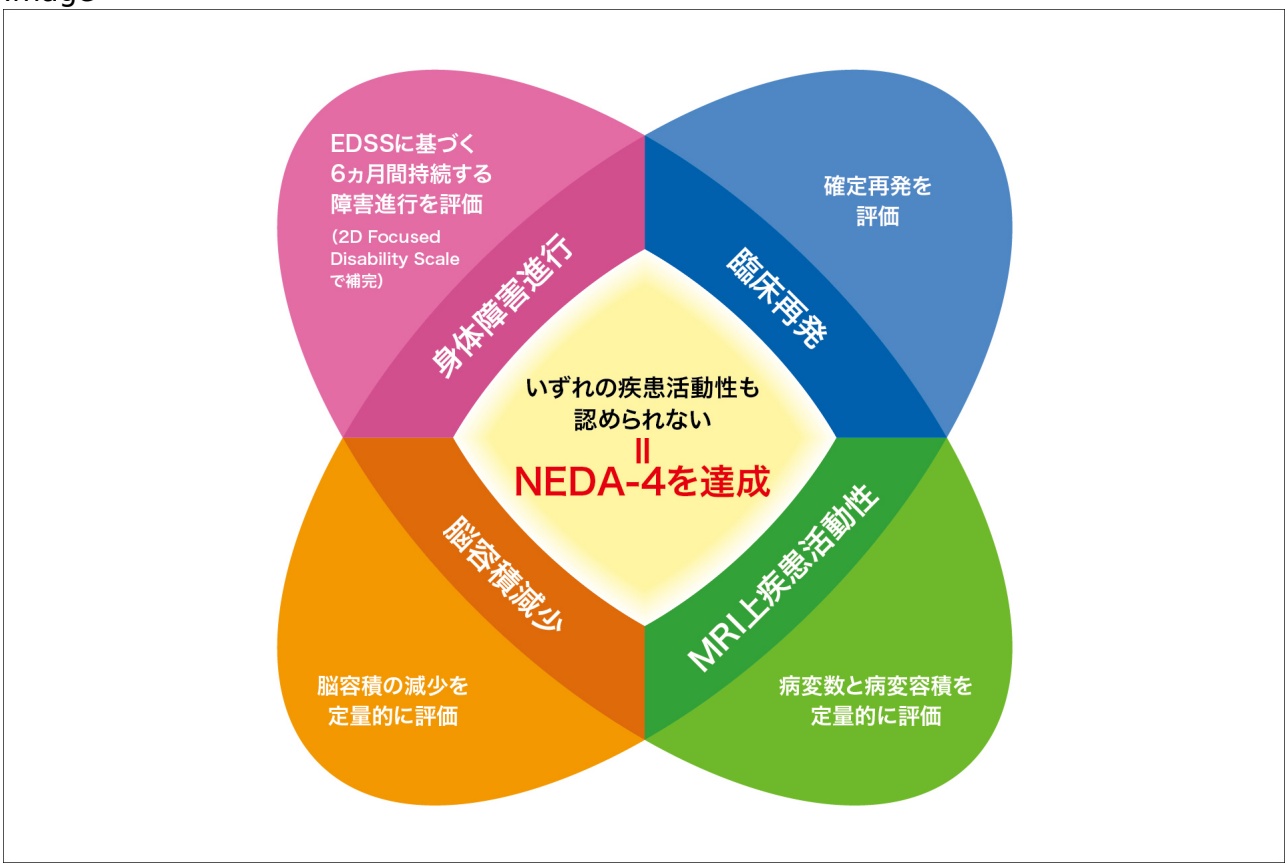

2□Ziemssen T et al□BMC Neurol 16□129, 2016□□□□
□□□□

□2□□□□□□□□□□□□□□□[2]□

Image

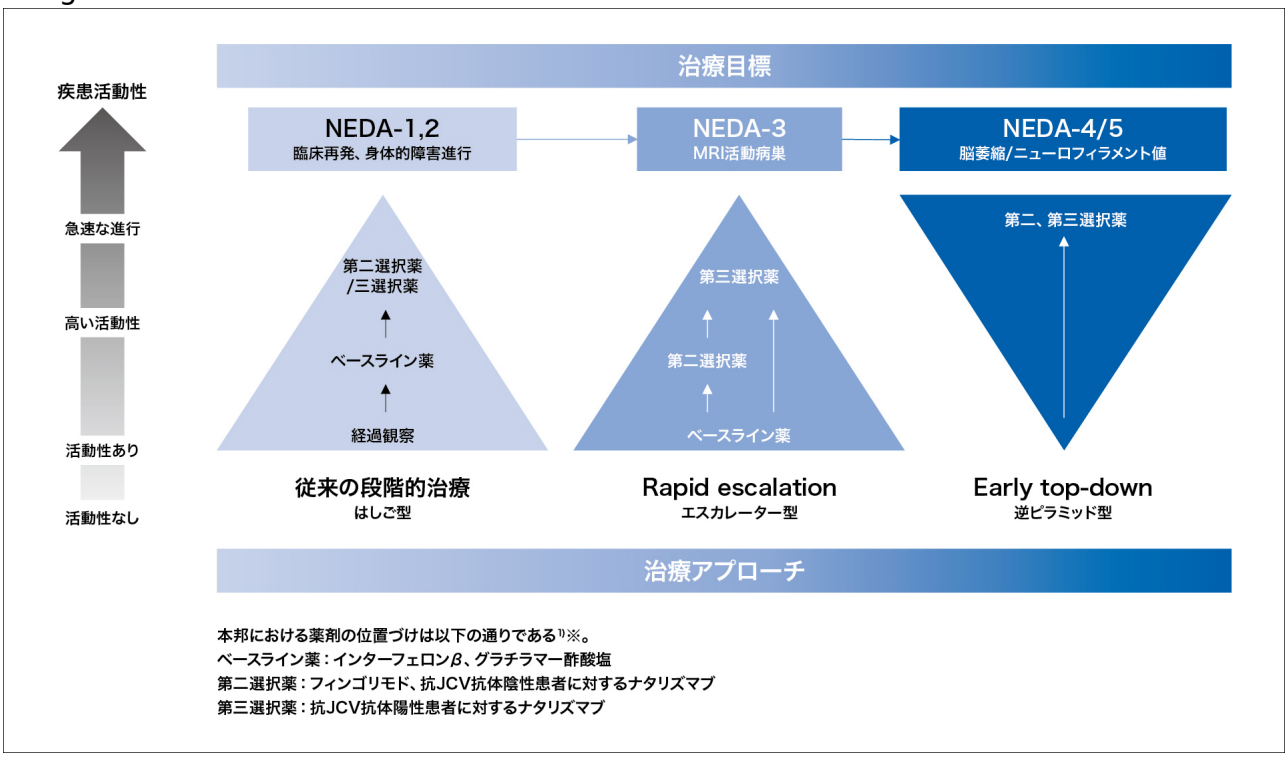

※□□□□□□□□□□□□□□□□□□□□□□□□□□□2017□□□□□□□2018□□□□□□□□□□□□□□□□□□□

□□□