[illegible]2012[illegible]International Tuberous Sclerosis Complex Consensus Conference[illegible]

# [illegible]TSC[illegible]

**International Tuberous Sclerosis Complex Consensus Group[illegible]**

## [illegible]

[illegible]TSC[illegible]2018 World TSC Conference[illegible]2018[illegible]7[illegible]

□□□□□[1]□□□□□□□□□

□□□□□□□□□2012□□□□□□□□□□□□□□□□□□[2,3]□□□□□□□□□□□□□□□□□□□□□□□□□□□□□□□□□□□□□□□□□□□□□□□□14□□□80□□□□□□□□□□□□□□□□□□□□□□□□□□□□□□□□□□□□□□□□□□Pediatric Neurology□□□□□□□□□□□□□□□□□□□□□□□□□□□□□□□□

## □□□□□□□□□□□□□□□□□□□□□□□□□□□□□□□□□□□□□□□□
## □**Northrup H, et al. Pediatr Neurol 2021; 123: 50-66.**□

## □□□□□□□□□□□

- □□□□□□□[□]□□□□□□□□□□□□□□□*TSC1*□□□*TSC2*□□□□□□□□□□□□□□□□□□□□□□□□□□□□□□□□□

  □□□□□□□□□□□□□□□□□□□□□□□□□□□□□□□□□□□□□□□□□□□□□□□□□□□□□□□□□□□□□□□□□□□□□□□□□□

[illegible]

- [illegible]“[illegible]”[illegible]“[illegible]/[illegible]”[illegible]
- [illegible]“[illegible]”[illegible]6[illegible]7[illegible]

  Northrup H, et al. Pediatr Neurol 2021; 123: 50-66.

## [illegible]1[illegible]

**A.** [illegible]

- [illegible]DNA[illegible]*TSC1*[illegible]*TSC2*[illegible]
- [illegible]/[illegible]*TSC1*[illegible]*TSC2*[illegible]
  [illegible]Hoogeveen-

Westerveld M, et al. 2011, 2012 and 2013, Dufner Almeida LG, et al. 2020□□□□□□□[□]□□□
□□□□*TSC1*□□□*TSC2*□□□□□□□□□□□□□□□□□□□□□□□□□□□□□□□□□□□□□□□□

- *TSC1*□□□*TSC2*□□□□□□□□□□□□□□□□□□□□□□□□□□□□□□□□□□□□□□□□□□□□□□□□□□□□□□□□□□□□□□□ □□□□□□ACMG□America College of Medical Genetics□□□□□□□Richards S, et al. 2015□□□□ □□□□□□□□□□□□□□□□□□□□□□□□□□
- □□□□□□□□□10□15□□□□□□□□□□□□□□□□□□□□□□□□□□□□□□*TSC1*□□□*TSC2*□□□□□□□□□□□□□□□□ □□□□□□□□□□□□□□□□□□□□□□□□□□□□□□□□□□□□□□□□□□□□□□□□□□

- □□□□□□□□□□NGS□□□□□High-read-depth□□□□□□□□NGS□□□NGS□□□□□□□□□□□□□□□□□□□□□□ □□□□□□□□□□□□□□□□□□□□□□□□□□□□□□□□□□□□□□□□□□□□□□□□□□□□□□□□□□□□□□□□□□□□□□□□ □□□□□□□□□Tyburczy ME, et al. 2015□□□□□□□□□□□□□□□□□□□□□□□□□□□□□□□□□□□□□□□□□□□ □□□□□□□□□□□□□□□□□□□□□□□□□□□□□□□□□□□Giannikou K, et al. 2019□□□□□□□□□□□□□□□□□ □□□□□□□□Peron A, et al. 2018□□

□□□□□□□□□□□□□□□□□□□□□□□□□□□□□□□□□□□□□□□□□□□□□□□□□□□□□□□□□□□□□□□□□□□□□□□□ □□2022□4□□□□□□□□□□□□□□□□

**B.** □□□□□□□

| □□□ | □□□ |
|---|---|
| □□□□□□(3□□□□□□5mm□□) | □□□(Confetti)□□□□ |
| □□□□□□□(3□□□)□□□□□□□□□□□ | □□□□□□□(3□□□□) |
| □□□□□(2□□□) | □□□□□□(2□□□) |
| □□□□□□□□(□□□□□) | □□□□□ |
| □□□□□□□□ | □□□□□□ |
| □□□□□□□□□□□□□□□□□□ | □□□□□□□ |
| □□□□□□2□□□□ | □□□□□□ |
| □□□□□□□□□□□ | |
| □□□□□ | |
| □□□□□□□□(LAM)* | |
| □□□□□□(2□□□)* | |

□□□□□definite TSC□□□□□□□2□□□□□□□□□□1□□□□□□2□□
□□□□□possible TSC□□□□□□□1□□□□□□□□□□2□□□□
□□□□□□□□*TSC1*□□□*TSC2*□□□□□□□□□□□□□□□□□TSC□□□□□□TSC□□□□□□□□□□□□□□□□□□□□□□□TSC1□□ □TSC2□□□□□□□□□□□□□□□□□□□□□□□□□□□□□□□□□□□□□□□□□□□□□□□□□□□□□□□□□□□□□TSC□□□□□□ □□□□□□□□□□□□□□□□□□□□□□□□□□□□□□□□□□□□□□□□

□LAM□□□□□□□□2□□□□□□□□□□□□□□□□□□□□□□□□□□□□□□□□□□□□□□□□□□□□□□□
TSC□□□□□□□

Northrup H, et al. Pediatr Neurol 2021; 123: 50-66, 52-53.

□□□□□□□□□□□□□□□□□□□□□□□□NCCN□□□□□□□National Comprehensive Cancer Network.

Development and update of guidelines. Available at: https://www.nccn.org/guidelines/guidelines-process/development-and-update-of-guidelines.[illegible]
[illegible](表2)[illegible]
[illegible]

[illegible]2022[illegible]4[illegible]

[illegible]2[illegible]

| [illegible] Category | [illegible] | [illegible] |
|---|---|---|
| Category 1 | [illegible] | 1[illegible]class I[illegible]2[illegible]class II[illegible]3[illegible]class III[illegible] |
| Category 2A | [illegible] | 1[illegible]class II[illegible]2[illegible]class III[illegible] |
| Category 2B | [illegible] | 1[illegible]class III[illegible]2[illegible]class IV[illegible] |
| Category 3 | [illegible] | [illegible]class I-IV[illegible] |

**[illegible]class[illegible]**

class I: [illegible]
class II: [illegible]
class III: [illegible]
class IV: [illegible]

## [illegible]

**[illegible]3[illegible]**

## [illegible]

[illegible]3[illegible]*[illegible]

[illegible]2022[illegible]4[illegible]

[illegible]

□MRI□□□□□□□□□□□□□□□SEN□□□□□□□□□□□□□□□□□□SEGA□□□□□□□□□MRI□□□□□□□□□□□□□□
□□□□□□□□□□□□□CT□□□□□□□□□□□□□□□□□□□□MRI□□□□□□□□□□□□□□□□□□□□□□□□□□□□□□

□□□□□□□□□□□□□□□□□□□□□□□□□□□□□□□□□□□□□□□□□□□□□□□□□□

□□□□□□□□□□□□□□□□□□□□□□□EEG□□□□□□□□□□□□□□□□□□□□□□□□□□□□□□□□□□□□□□□□□□□□□
□□□□□EEG□□□□□□□□□□□□□□□□□□□□□□□□□□8□24□□□□□EEG□□□□□□□□□
□□□□□□□□□□□□□□□□□□□□□□□□□□□□□□□□□□□□□□□□□□□□□□□□□□□□□□□□□□□□□□□□□□□□□□
□□□□□□□□□□□□□□□□□□□□□□□□□□□□□□□□□□□□□□□□□□□□□□□□□□□□□□□□□□□□□□□□□□□□□□
□□□□□□□□□□□□□□□□□□□□□□

MRI□□□□□□□□□CT□□□□□□□□□□□□□

## □□□□□□□□□□□□□□□□TAND□

TAND

Image

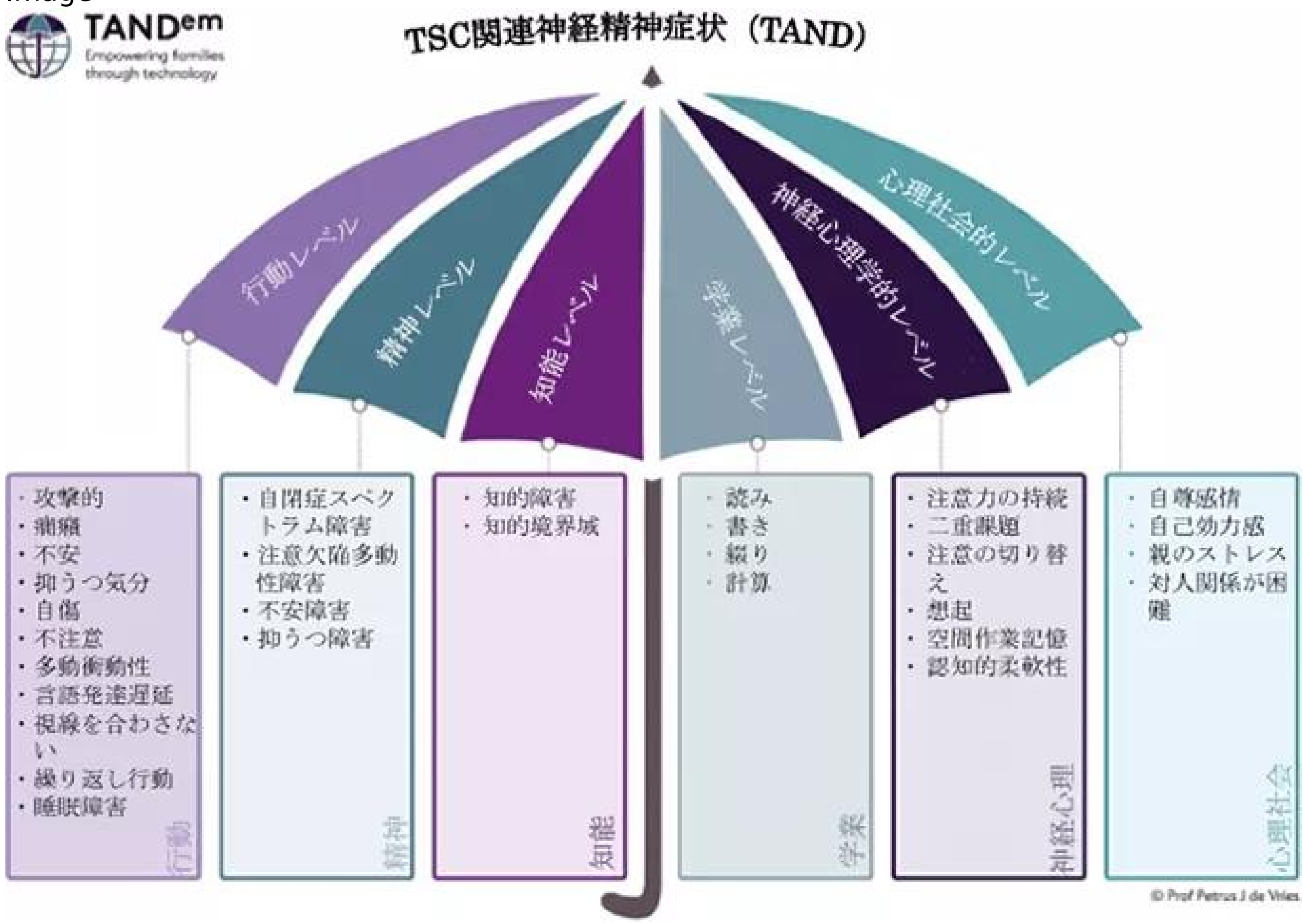


□□□□□□□□□□□□□□□□□□□□□□□□□□□□□□□□□□□□□□□□□□□□□□□□□□□□□□□□□□□□□□□□□

□□□□□□□□□□□□□□□□□□□□□□□□□□□□□TAND□□□□□□□□□□□□□□□□□□□□□

□□□□□□□TAND□□□□□□□□□□□□□□□□□□□□□□□□□□□□□□□□□□□□□□□□□□□□□□□□□□□□□□□□□□□□

TAND□TSC-associated neuropsychiatric disorders□□□□□□□□□□□□□□□□□□□□□□□□□□□□□□□□□□□□□□□□□□□□□□□□□□□□□□□□□□□□□□□□□□□□□□□□□□□

## □□

[illegible]MRI[illegible]
[illegible]MRI[illegible]

[illegible]CT[illegible]GFR>60mL/min/1.73m2[illegible]
[illegible]

[illegible]MRI[illegible]MRI[illegible]MRI[illegible]
[illegible]

[illegible]

GFR[illegible]

MRI[illegible]CT[illegible]GFR[illegible]

□

□□□

VEGF-D□□□□□□□□□□-D□CT□□□□□□□□□□□□□

□□

□□□□□□□□□□□□□

□□□

□□□

□□□

□□□

□□□

□□□□□□□□□□□□□□**SEGA**□

□□□□□□□□□□□□□□□□□□□□□□□□□□SEGA□□□□□□□□□□□□□□□□□□□□□□□□□□□□mTOR□□□□□□□□□□□□□□□□□□□

□□□□□□□□□□□□□□□□□□□□SEGA□□□□□□□□□□25□□□□□□□□□□□□□□□□□□□□□□□□□□□□1□3□□□□MRI□□□□□□□□□□□□□□□□□□□

TAND□□□□□□□□https://tandconsortium.org/checklists/□□□□□□□□

| |
|---|
| □□□□

□□3cm□□□

□□□□□□□□□□□□□□□□CT□□□□□□□□□□□□□LAM□□□□□□□□□□□□□□□□□□□□□□□□□□□□□LAM□□□□□□□□□CT□□□□□□□□□□□□□□□□□□□

□□□□□□□□□□□□□□□□□□□□□□□□VEGF-D□□□1□□□□□□□□□□□□□□□□□□□

□□□□□□□□□□□□□□□□□1□□□□□□□□□□□□□□□□□

□□□□□□□□□□□□□□□□□□□□□□6□□□1□□□□□□□□□□

□□□□□□□□□□□□□□□□□□□

□□□

□□□

□□□

□□□

3) Krueger D. A, et al. Pediatr Neurol 2013; 49: 255-265.

□□□□□□□□□□□□□□□□

□□□□□□

---

**Source URL:** *https://www.pro.novartis.com/jp-ja/products/afinitor/tsc/guideline_01*